

The Arthroscopic Reconstruction of the CC ligament and Open Reconstruction of the AC ligament using a Semitendinosus Graft and Knot hiding CC-Clip Implants.

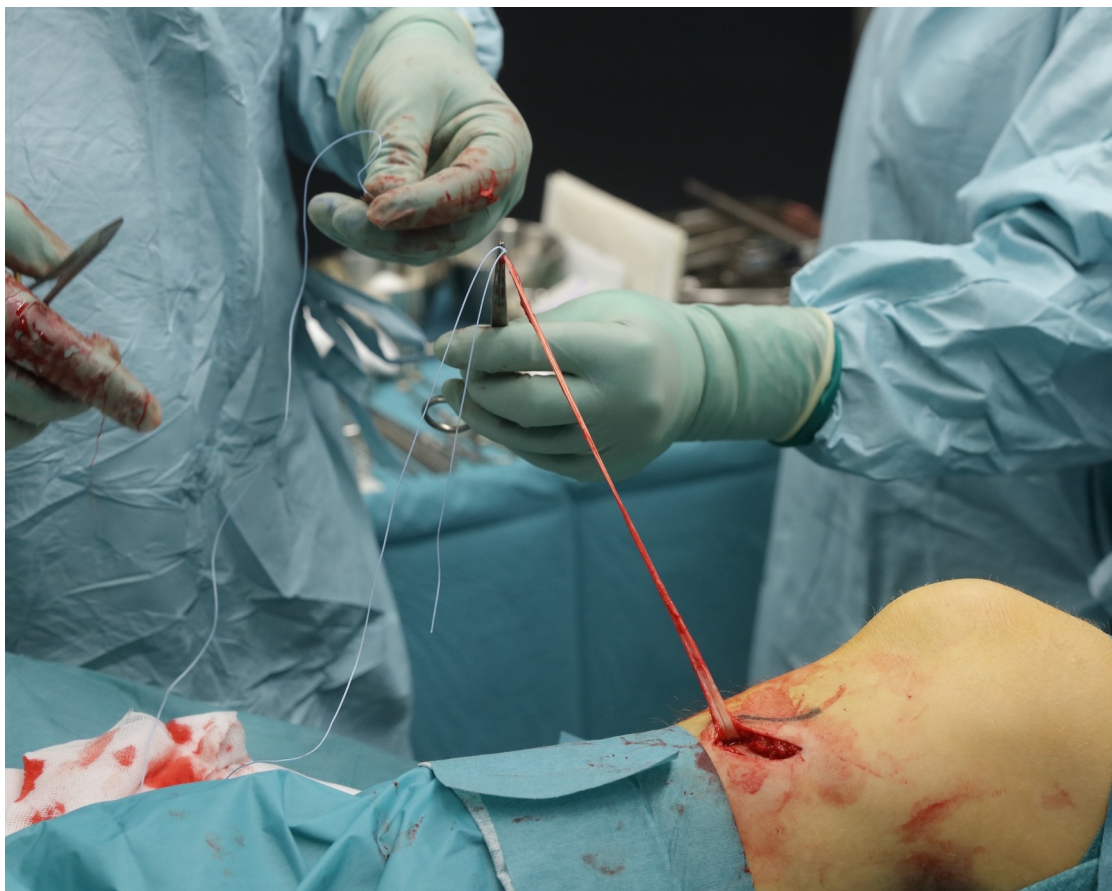The operative technique.

See also the *technical report*+ video:

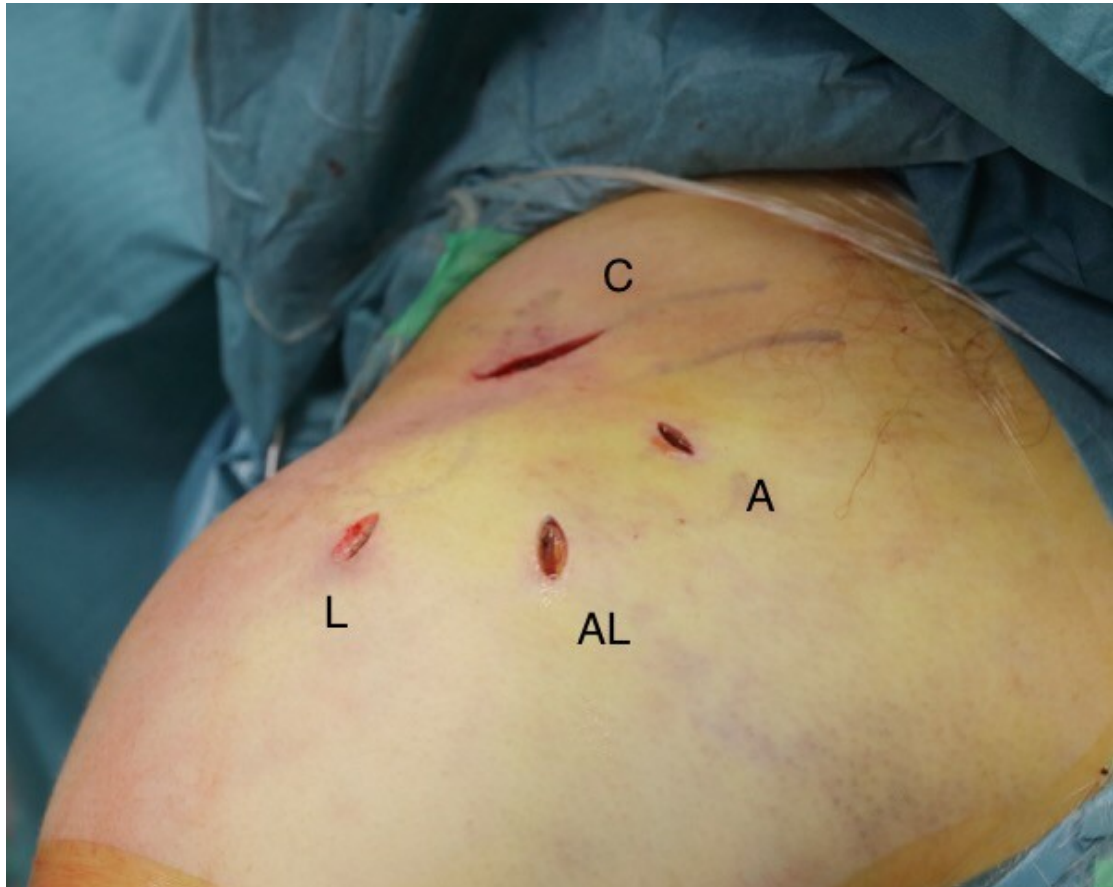
[https://authors.elsevier.com/sd/article/S2212-6287\(20\)30361-3](https://authors.elsevier.com/sd/article/S2212-6287(20)30361-3)

1. Semitendinosus graft and portals

The patient is placed in the beach chair position. The same side leg is prepared for hamstring harvesting.

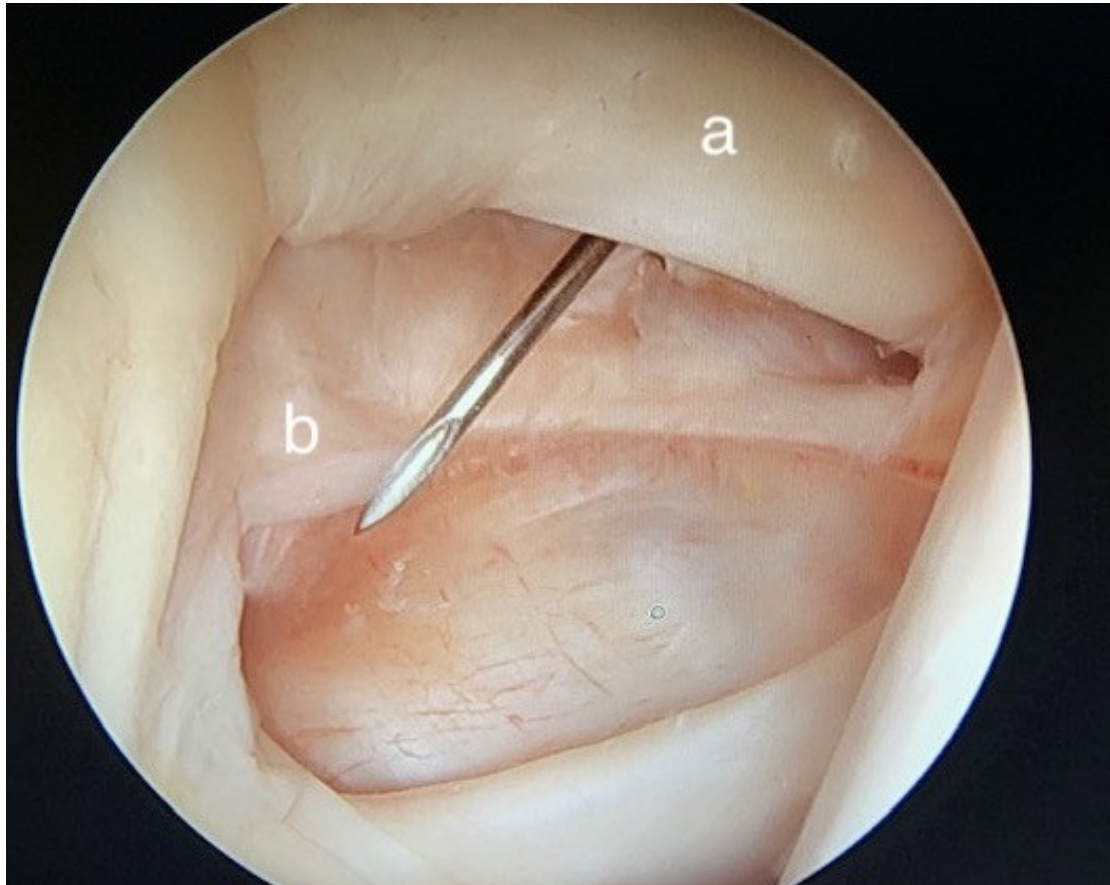


A semitendinosus autograft graft with a minimum length of 16 cm is harvested, and the passing suture is attached.



Five portals are used for the arthroscopy: the posterior (P), lateral (L), anterolateral (AL), anterior (A), and clavicular (C). The clavicular opening is made on the clavicle to expose the bone for subsequent drilling and passing the sutures. Later on, the incision is extended laterally over the AC joint.

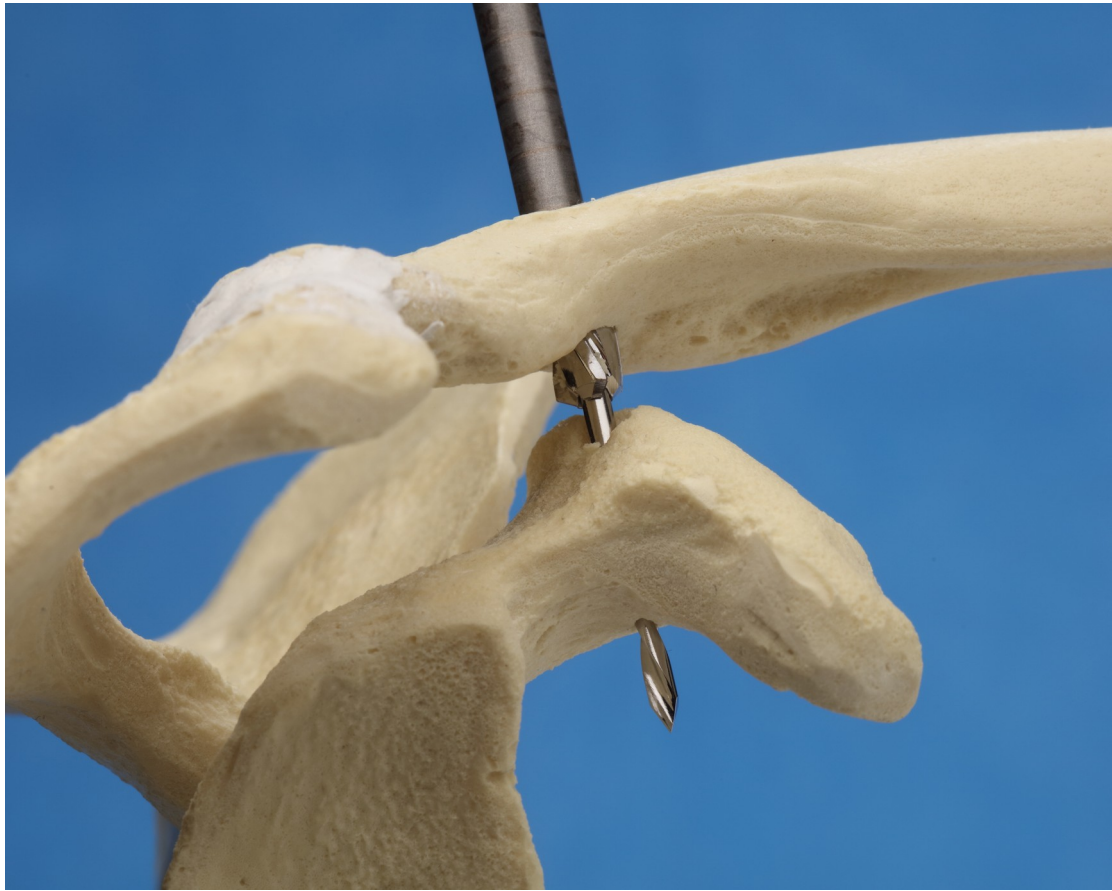2. CC reconstruction



1.1.

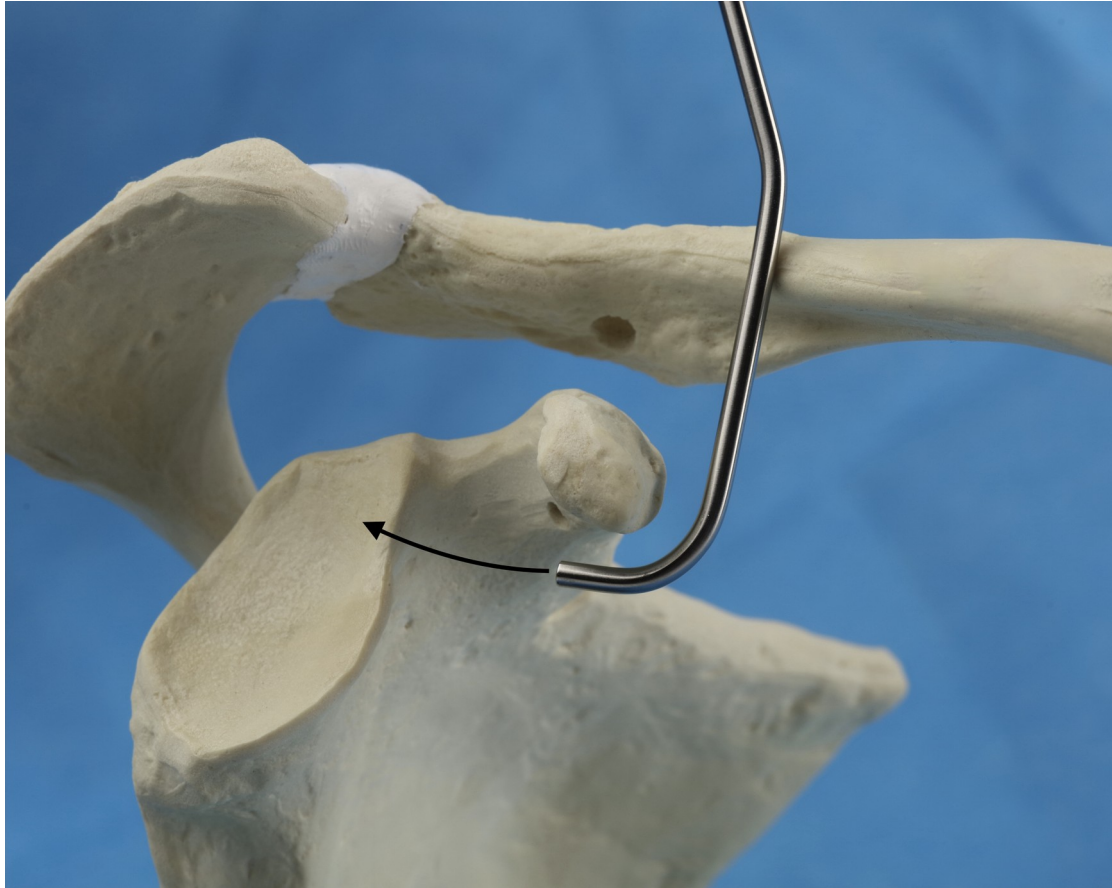
The operation is initiated by inserting the arthroscope into the joint through the posterior portal. The lateral portal is marked with a needle in front of the long head of the biceps-tendon (a) allowing the proper angle to the neck of the coracoid. The coracoid is exposed through the interval (b).

The arthroscope is then moved to the lateral (L) portal. The primary camera position is in the L portal. The AL and A portals are established with the help of a needle to reach the neck of the coracoid. The location of the clavicular incision (C) is also positioned using a needle. Easy access to the coracoid neck area from the dorsal clavicle and from the anterior clavicle is crucial.



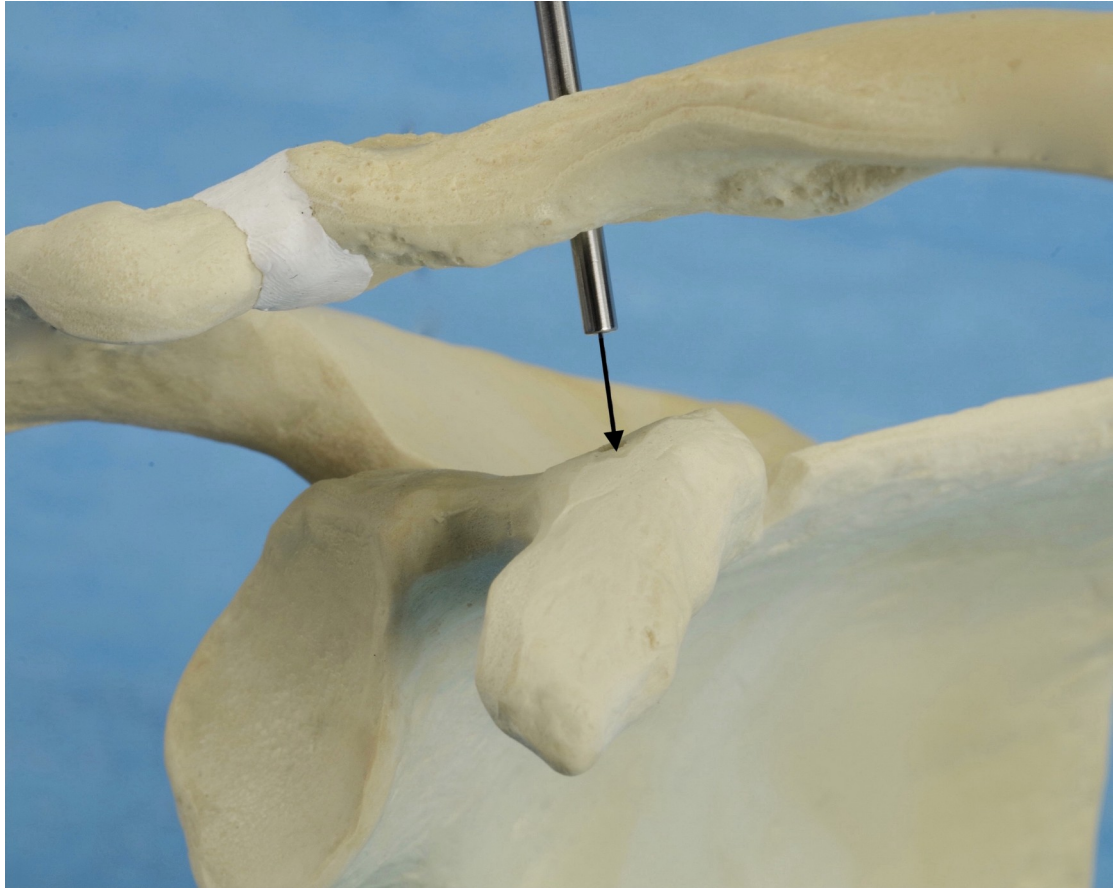2.1.

A 2.4-mm guide pin is drilled through the clavicle and the coracoid using drill guides. The clavicular drill hole is located centrally on the clavicle approximately 2.5 cm proximal from the AC joint. The coracoid drill hole is centrally located as proximally as possible. The clavicular drill hole/cortex is then enlarged to 5.5 mm.



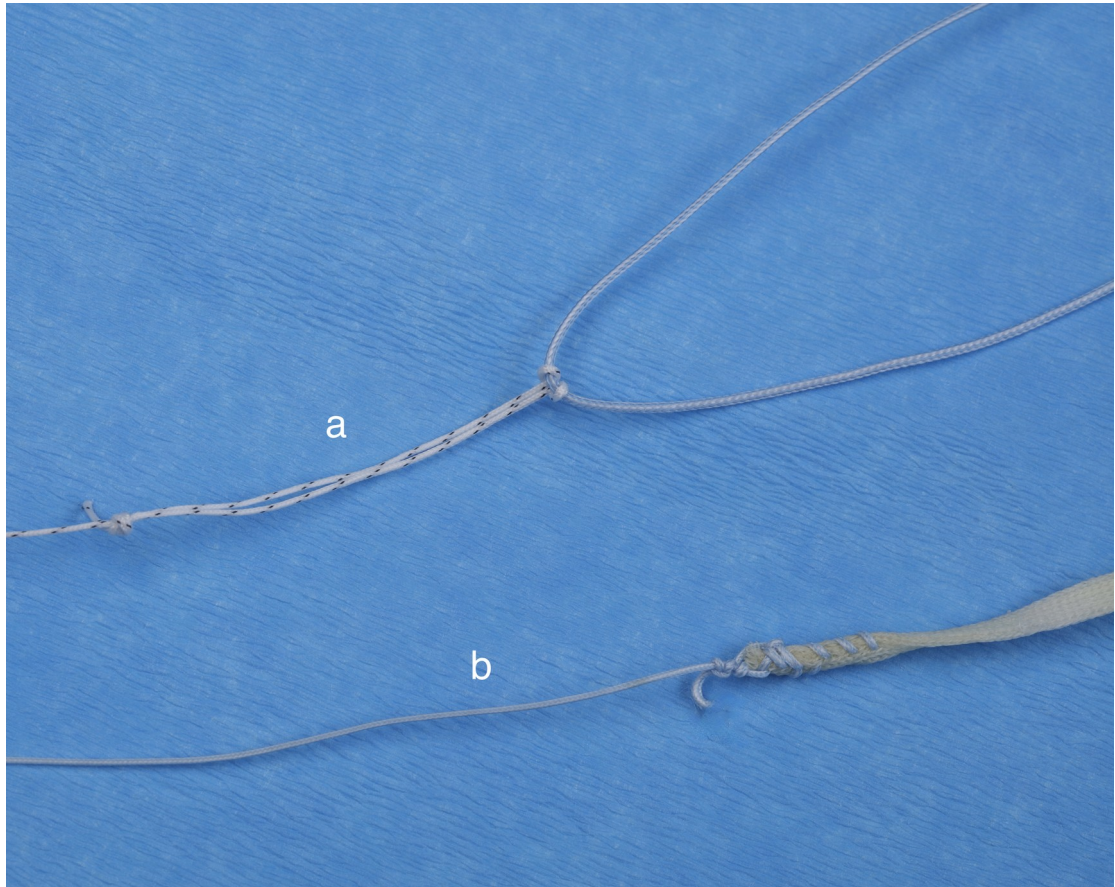
3.1

The Hook Guide is placed in front of the clavicle and the border medial to the coracoid in order to pass the lasso under the coracoid. The nitinol lasso is fed with the welded end first (arrow). The proximal end of the lasso can then be retrieved through the clavicular drill hole using a suture passer.

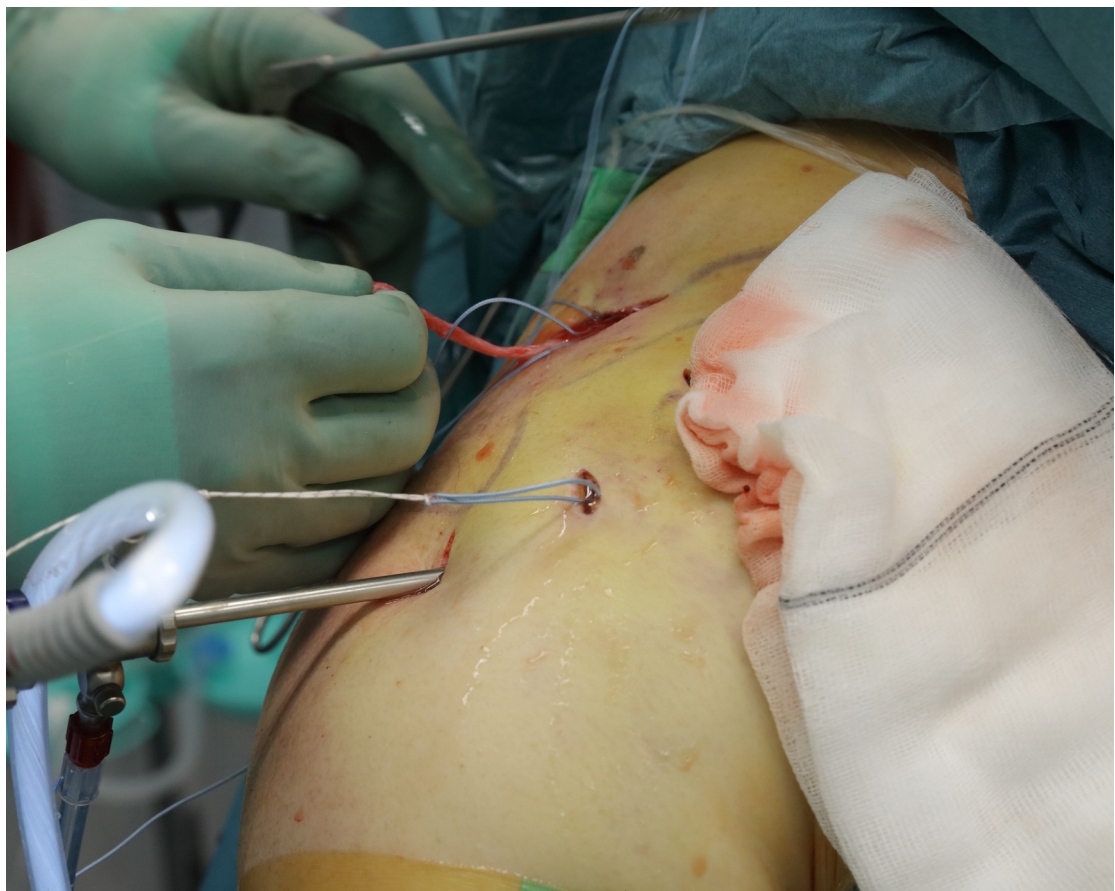
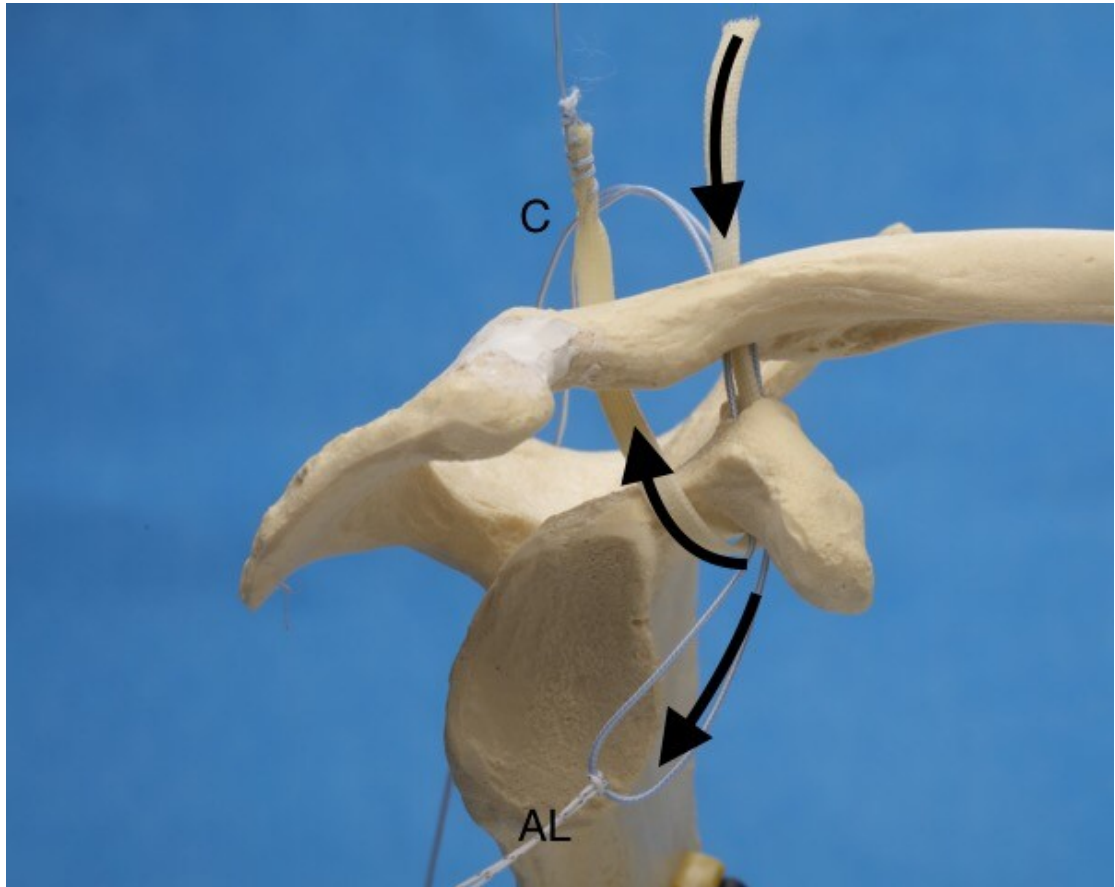


4.1.

The straight Lasso Guide is used to pass the lasso through the drill holes. The nitinol loop is fed through with the welded end first (Arrow).


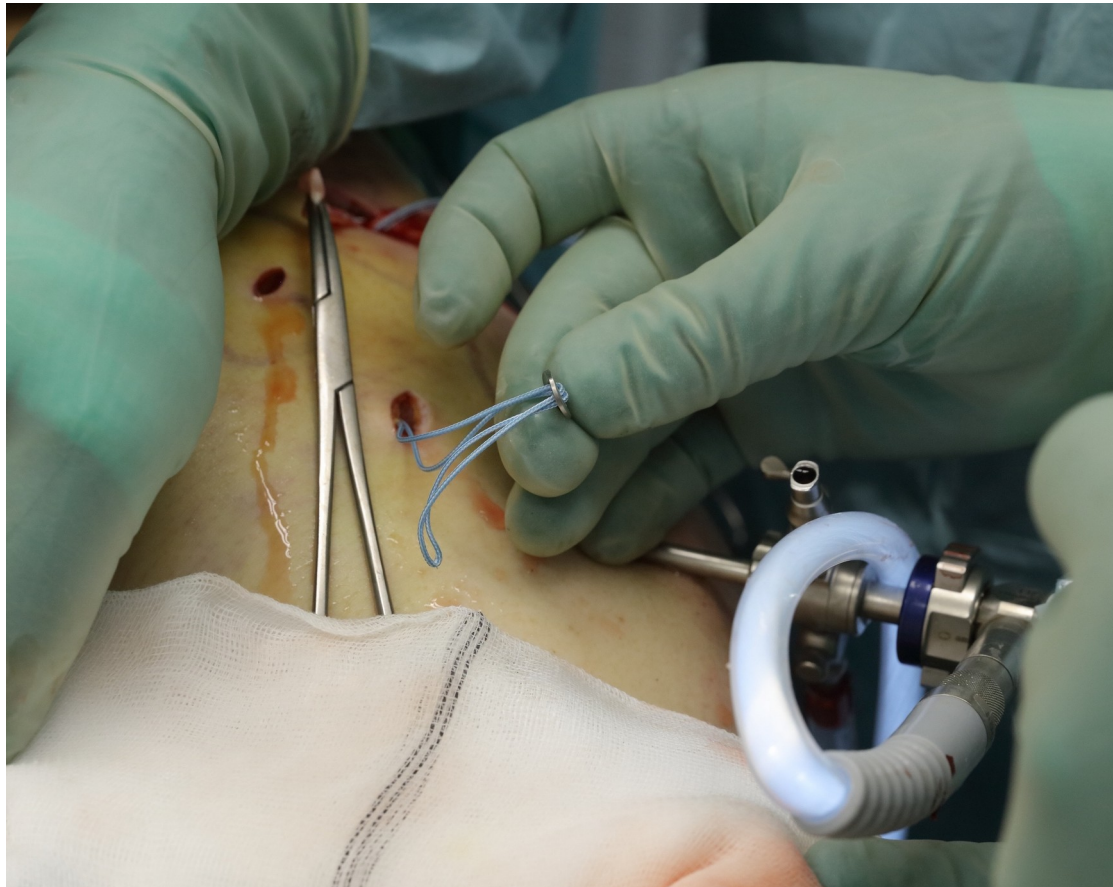


The passing sutures attached to the interconnecting suture loop (a) and the tendon graft (b).



5.1.

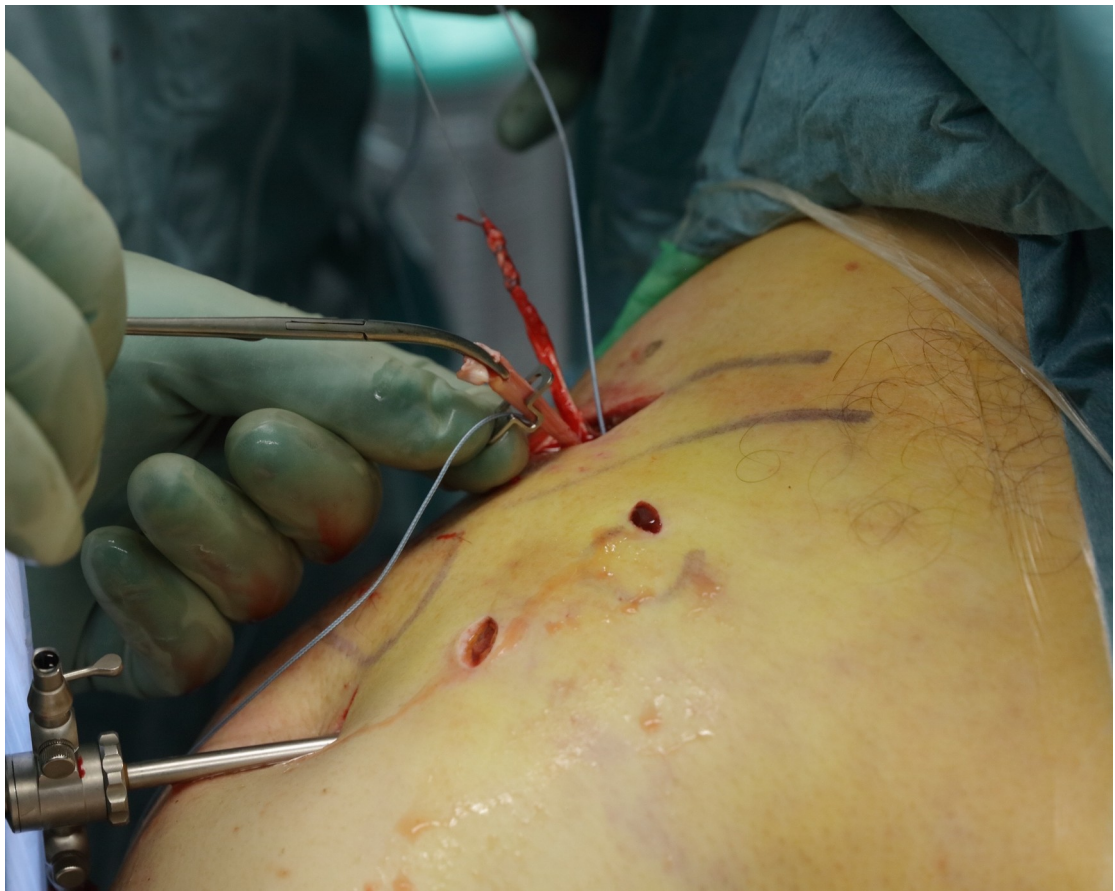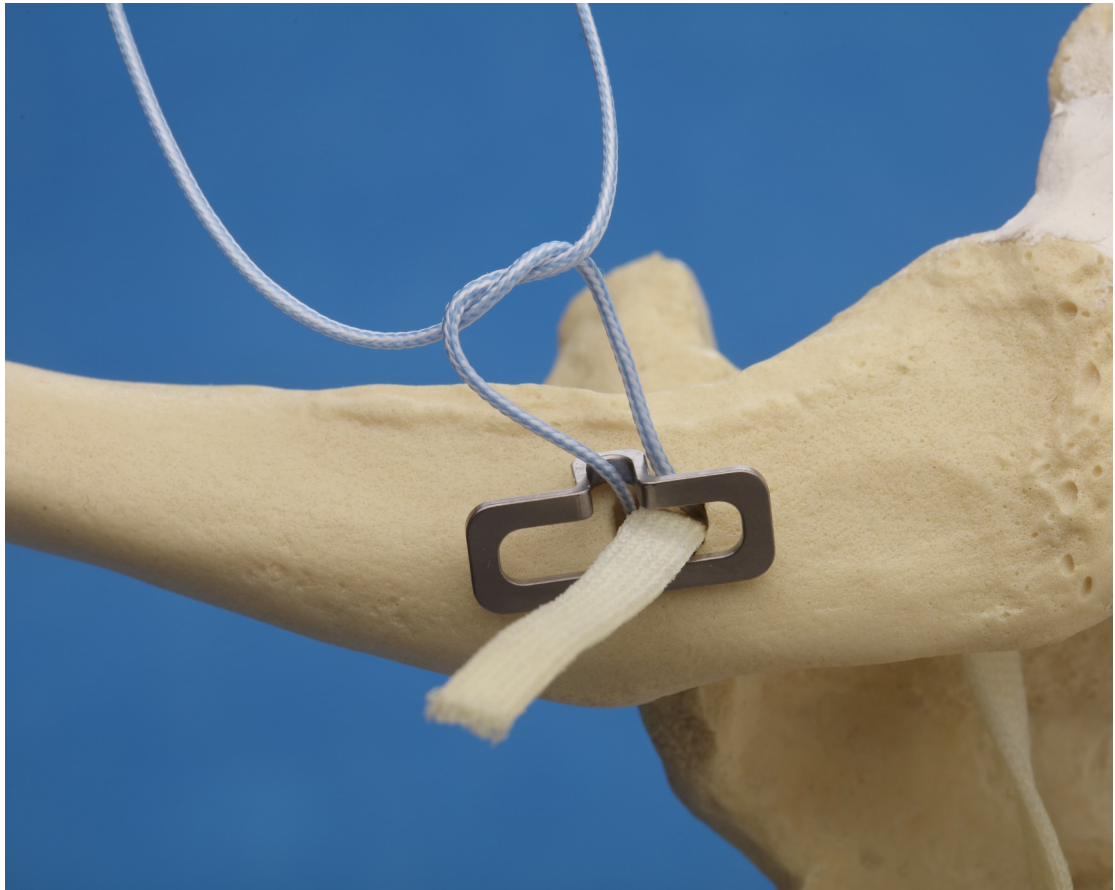
Using the passing suture, the graft is pulled through the clavicular drill hole under the coracoid, and then to the clavicular opening behind the clavicle (C). The interconnecting suture loop is passed through the clavicular and coracoid drill holes to the anterolateral portal (AL).



6.1.

The suture loop is slid through the Subcoracoid Clip eyelet and then through the other Clip eyelet. The loop is then thrown over the Clip and pulled taut creating a firm sling over the Clip crossbar.

The Subcoracoid Clip is then pulled in by the suture ends and the Subcoracoid Clip sets into place underneath the coracoid.

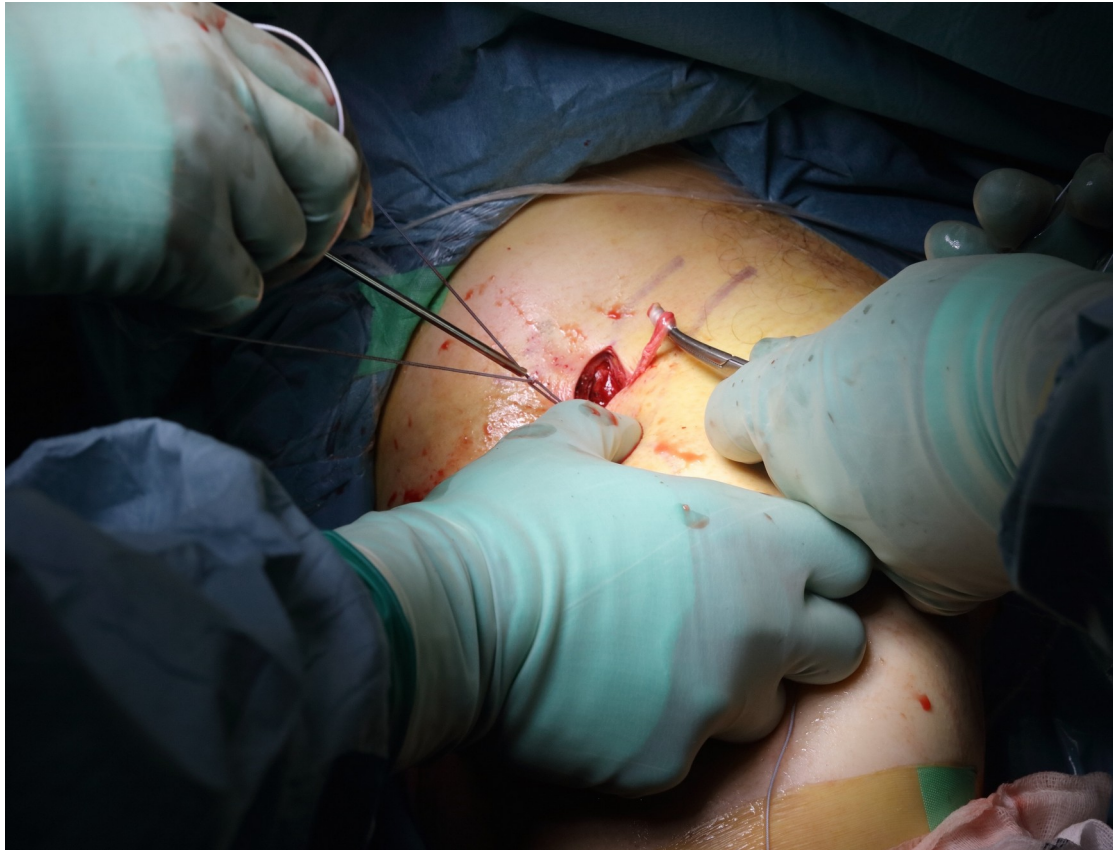

7.1.

The end of the anterior graft limb and the posterior end of the interconnecting suture are now slipped through the Clavicular Clip and the Clip is positioned onto the clavicular drill hole. The suture is left untied at this point.

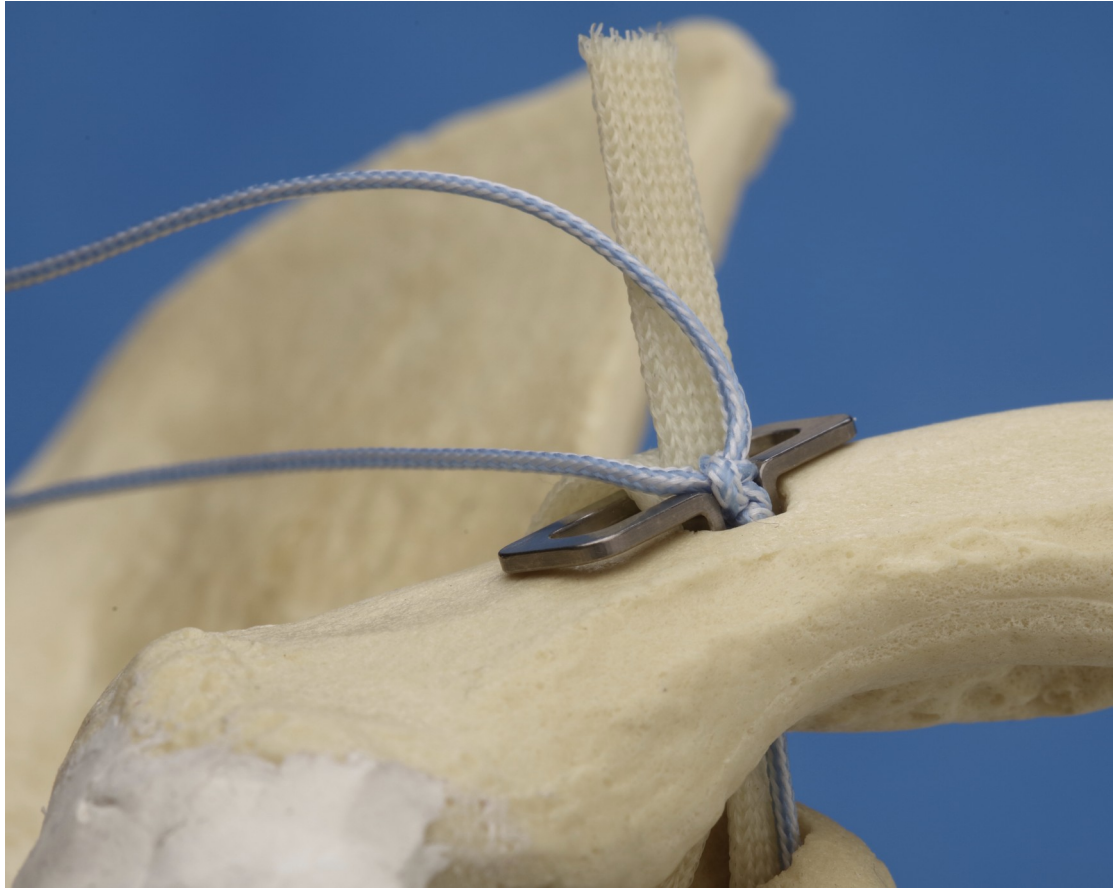3. AC reconstruction and finalizing the operation

The clavicular wound is extended over the AC joint. The AC joint capsule is opened along its fibers. The distal clavicle is carefully mobilized and the distal clavicle may be resected in order to easily reduce the AC joint.



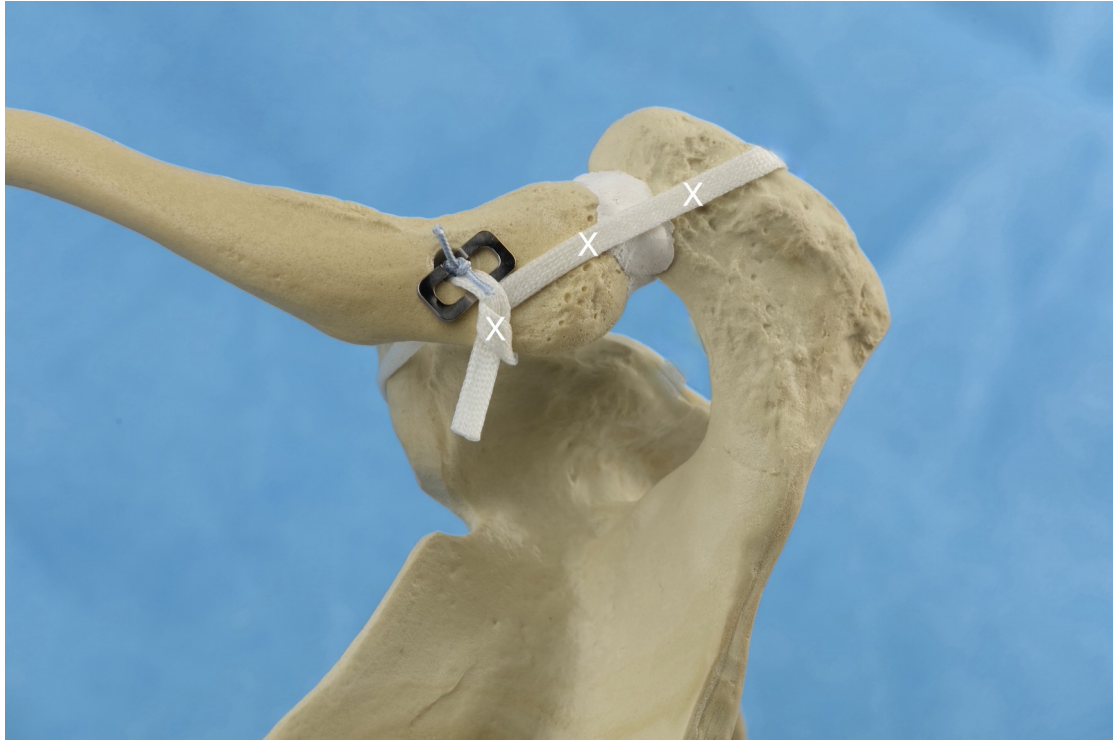1.2.

The clavicle is now repositioned with support from the elbow. The repositioning is checked under visual control. The graft limbs are tensioned. Keeping the distal clavicle down and the graft taut, the interconnecting suture is tensioned and tied.



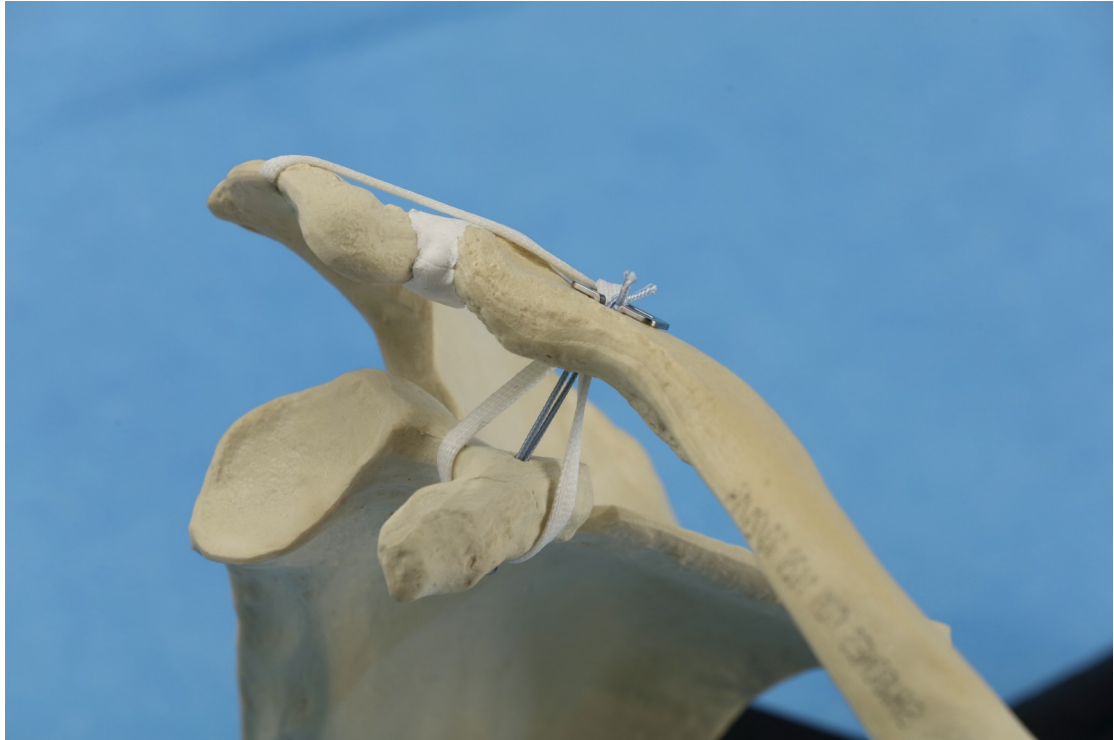2.2.

Once the sutures are tied the Clavicular Clip loop is allowed to sink into the clavicular drill hole hiding the knot.



3.2

When the CC reconstruction is finished, the superior AC ligament is reconstructed with the longer dorsal end of the tendon graft. The graft limb is fixed with sutures on both sides of the AC joint. The AC capsule is then plicated tight over the reconstruction. Site of the sutures (X).

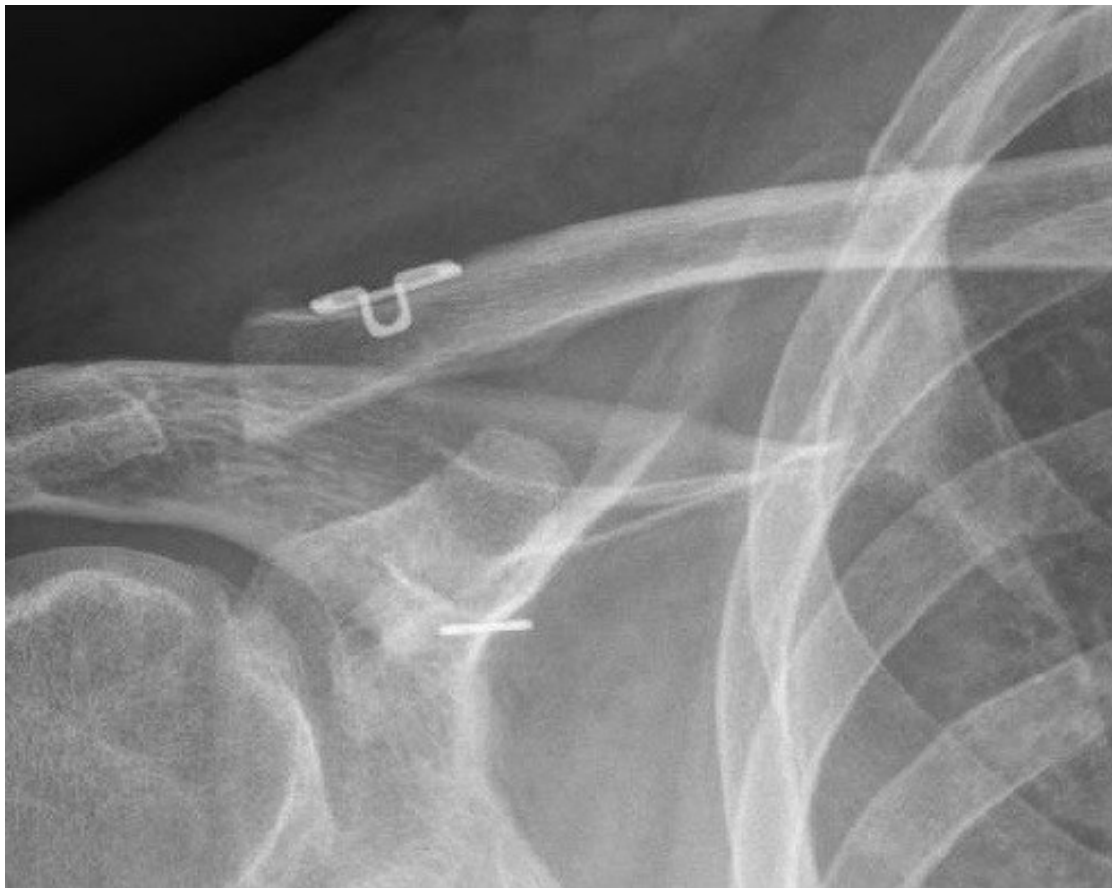

4.2

With all the reconstructions completed, the arthroscopic portals are closed with interrupted sutures while the clavicular wound is closed meticulously in layers.

4. Postoperative treatment

An arm sling is worn for six weeks post-surgery. The patient is allowed to perform light rotatory movements and passive arm lifting within the limits of pain. Although the sling is removed after six weeks, active rehabilitation does not begin until eight weeks after - surgery to provide enough time for recovery.



Postoperative radiograph